Taylor & Francis
Taylor & Francis Group

Drug Design, Development and Therapy

ISSN: 1177-8881 (Online) Journal homepage: www.tandfonline.com/journals/dddt20

"An Effective Solution to Accelerate the Healing of Complex Ulcers Using Recombinant Human Epidermal Growth Factor (Intralesional Application): A Review"

Maria Teresa Cacua Sánchez & Carlos Alberto Carillo Bravo

To cite this article: Maria Teresa Cacua Sánchez & Carlos Alberto Carillo Bravo (2025) "An Effective Solution to Accelerate the Healing of Complex Ulcers Using Recombinant Human Epidermal Growth Factor (Intralesional Application): A Review", Drug Design, Development and Therapy, , 5615-5631, DOI: 10.2147/DDDT.S517489

To link to this article: https://doi.org/10.2147/DDDT.S517489

© 2025 Cacua Sánchez and Carillo Bravo.

Published online: 01 Jul 2025.

Submit your article to this journal

Article views: 593

View related articles

View Crossmark data

Citing articles: 5 View citing articles

Full Terms & Conditions of access and use can be found at
https://www.tandfonline.com/action/journalInformation?journalCode=dddt20

Drug Design, Development and Therapy

Dovepress
Taylor & Francis Group

Open Access Full Text Article

REVIEW

"An Effective Solution to Accelerate the Healing of Complex Ulcers Using Recombinant Human Epidermal Growth Factor (Intralesional Application): A Review"

Maria Teresa Cacua Sánchez[1], Carlos Alberto Carillo Bravo[2]

[1]Peripheral Vascular Surgery and Angiology, University El Bosque, Management and Health Services, University Sergio Arboleda, Occidente de Kennedy Hospital, Ambulatory Surgery Center, Bogotá, Colombia; [2]Epidemiologist Universidad Del Rosario, Clinical Epidemiology - Colombian Society of Preventive Medicine, Bogotá, Colombia

Correspondence: Maria Teresa Cacua Sánchez, Peripheral Vascular Surgery and Angiology, University El Bosque, Management and Health Services, University Sergio Arboleda, Occidente de Kennedy Hospital, Av. 1 de Mayo #40B-54, Bogotá, 111611, Tel +57-1-3057470125, Email mcacua@gmail.com

Abstract: Chronic and complex ulcers of the lower limbs constitute a common, persistent, and clinically significant complication, particularly in patients with diabetes, peripheral vascular disease, and other dermatological conditions. These lesions are characterized by impaired healing, high recurrence rates, and a substantial risk of infection, amputation, and functional decline, thereby posing a considerable burden on both patients and healthcare systems. In response to this unresolved clinical need, recombinant human epidermal growth factor (rhEGF) has emerged as an innovative and effective therapeutic strategy. By stimulating cell proliferation, angiogenesis, and tissue regeneration, rhEGF reactivates essential biological processes that are typically impaired in such lesions, thereby promoting accelerated and functional wound healing. Additionally, its anti-inflammatory and antioxidant properties contribute to reducing associated complications, such as infection. Accumulated scientific evidence over recent years has strengthened the support for its clinical use, with multiple studies—including controlled trials, retrospective analyses, and systematic reviews—demonstrating consistent outcomes across various clinical settings. In practice, rhEGF has been established as a safe and effective therapeutic tool with the potential to transform the conventional management of chronic and complex ulcers, improving clinical outcomes and enhancing patients' quality of life.

Keywords: chronic venous insufficiency, CVI, diabetic foot ulcer, DFU, complex ulcers, epidermal growth factor, EGF, recombinant human epidermal growth factor, rhEGF, amputation, pressure injuries, oxidative stress, burns, grafts, inflammation

Key Messages

1. Prevalence of Chronic Ulcers: Chronic and complex ulcers, especially in the lower extremities, are common complications in patients with conditions like diabetes, peripheral vascular disease, and skin disorders.
2. Role of Recombinant Human Epidermal Growth Factor (rhEGF): rhEGF has been found to be an effective treatment for healing these ulcers by reactivating the natural wound-healing process, promoting cell proliferation, angiogenesis, and reducing inflammation and infection risks.
3. Strong Scientific Evidence: Numerous studies from different researchers across various countries have consistently shown positive results, indicating that rhEGF is a scientifically supported and generalizable treatment for chronic and complex ulcers.

Introduction

Currently, advancements in medicine have contributed to an increase in the population's life expectancy. However, improvements in quality of life have not necessarily kept pace with the increase in longevity. It has been observed that

Received: 10 February 2025
Accepted: 27 May 2025
Published: 1 July 2025

© 2025 Cacua Sánchez and Carillo Bravo. This work is published and licensed by Dove Medical Press Limited. The full terms of this license are available at https://www.dovepress.com/terms.php and incorporate the Creative Commons Attribution – Non Commercial (unported, v4.0) License (http://creativecommons.org/licenses/by-nc/4.0/). By accessing the work you hereby accept the Terms. Non-commercial uses of the work are permitted without any further permission from Dove Medical Press Limited, provided the work is properly attributed. For permission for commercial use of this work, please see paragraphs 4.2 and 5 of our Terms (https://www.dovepress.com/terms.php).

this type of population can develop issues that clearly compromise their quality of life. One of these issues is the loss of skin integument, which manifests as skin alterations, loss of subcutaneous tissues, and sometimes can even compromise muscles and bones. This leads to ulcers or wounds that vary significantly in nature and range from simple wounds defined as ruptures in the skin or other tissues caused by injury or cut to more complex wounds characterized by being chronicity or inability to heal spontaneously due to other factors, requiring specialized attention.[1,2] A wound is an injury to the skin or mucous membrane, characterized by tissue loss and exposure of underlying layers compromising patients with chronic diseases.[3]

A change has been observed in the terminology used for wounds that do not heal properly and are associated with chronic diseases. These wounds are no defined as complex wounds. For the purposes of this article and according to the aforementioned definitions, we refer to this type of wounds as complex ulcers. For a simple wound to evolve into a complex ulcer, several characteristics are required, which have been widely defined and include the following: ulcers that have not healed within 3 months, presence of infection, compromised viability of the surface with tissue necrosis or altered circulation, and association with systemic pathologies that interfere with normal healing.[4]

These wounds can cause pain, disability, and significantly impact the quality of life of the affected individual. The most common types of complex wounds are related to the patient's physical factors, such as certain conditions, including diabetes mellitus, obesity, ischemia, peripheral vascular disease, cancer, organ failure, sepsis, mobility limitations, pharmacological treatments, and disruptions of the immune system. These conditions affect healing and can lead to various pathologies, including venous and arterial ulcers, diabetic foot ulcers, pressure ulcers, thermal or electrical burns, traumatic burns, necrotizing fasciitis, immunosuppression, and trauma. This type of lesion has become a significant challenge for health systems worldwide due to its increasing prevalence, and other risk factors such as an aging population, smoking, obesity, and diabetes.[5]

Studies show that this type of ulcers affect 1% of adult population and 3.6% of those over 65 years of age, increasing to more than 5% in those over 80 years of age.[6] During their lives, almost 10% of the population will develop one of these ulcers, with an ulcer-related mortality rate of 2.5%.[7] It is estimated that 7 million people in the United States suffer from ulcers that are difficult to treat and only 50% receive adequate treatment.[8] These ulcers pose a significant economic burden on patients and healthcare systems, with costs exceeding $20 trillion annually in the United States alone.[9] Untreated ulcers can lead to amputations, with a 30% likelihood of this outcome.[10] Unfortunately, 50% of amputations cause mortality within five years. In addition, during the COVID-19 pandemic, there was a 50% increase in amputations in 2020 compared to 2019.[11]

Among the causes of these types of ulcers are diabetic foot ulcers, with diabetes being one of the primary contributors to complex ulcers. More than 10% of the world population is diabetic or has a high risk of diabetes. Its prevalence is 6.3% worldwide, with North America having the highest prevalence (13%) and Oceania the lowest (3%). Prevalence in Asia, Europe and Africa is 5.5%, 5.1% y 7.2%, respectively.[12] Diabetes is one of the main causes of non-traumatic lower extremity amputation: 1 in 6 diabetic patients (25%) suffer from an ulcer during their lives, and 15% of those with diabetic foot require amputation.[13]

A review article by Armstrong et al revealed that diabetic foot ulcers are not just a condition that threatens the extremity, as the relative mortality rate 5 years after extremity amputation is 68%, only surpassed by lung cancer.[14] Therefore, diabetes can be considered a malignant disease. In fact, amputation only increases life expectancy of half of the diabetic patients who undergo the intervention by an average of 2 years.[15] Even with this invasive intervention, it is estimated that only about 56% of diabetics with ulcerative wounds survive more than 5 years after their initial manifestation.[16]

Another type of complex ulcers is the venous ulcer. These ulcers are the most severe complication of chronic venous insufficiency and account for more than half of all ulcers of the lower extremities. Their prevalence ranges from 1% to 3% and when including both healed and active ulcers, age is a significant predisposing factor, increasing in patients over 80 years of age up to 5%.[17] Its incidence is between 3 and 5 new cases per thousand people per year. These figures double in population segments over 65 years of age and are generally higher for women than for men.[18]

Regarding prognosis, 40–50% will remain active for 6 months to 1 year, 20% for more than 2 years, and up to 10% will continue for up to 5 years of evolution.[19] For the Latin American population, there is no reliable data on its incidence or prevalence but it is estimated that the prevalence may range between 3% and 6%.[20]

Other causes of complex ulcers include pressure injuries, necrotizing fasciitis, ulcers secondary to autoimmune diseases, traumatic ulcers, burns due to electricity or hyperthermia. Regardless of its etiology, its pathophysiological process is very similar. Keep in mind that skin has the ability to self-regenerate, and the physiological process of wound healing is achieved through four overlapping phases: hemostasis, inflammation, proliferation, and remodeling. Immediately after the injury originates, hemostasis occurs, characterized by vasoconstriction and blood coagulation, which results in the formation of a fibrin clot that provides a provisional matrix for cell migration. Platelets being the first to activate, secreting growth factors and cytokines, which attract fibroblasts, endothelial cells and immune cells that are responsible for starting the healing process.[21]

The next phase, known as the inflammatory phase, can last up to seven days. During this phase phagocytic cells such as neutrophils and macrophages play a crucial role. Neutrophils release reactive oxygen species and proteases that help in wound cleaning and sweeping cellular debris and preventing bacterial infection. Monocytes from the bloodstream also reach the site of injury and differentiate into tissue macrophages. Initially they differentiate into M1 macrophages that eliminate bacteria and non-viable tissues through phagocytosis, these being pro-inflammatory, but later they also differentiate into M2 macrophages that are responsible for releasing various growth factors such as Epidermal Growth Factor (EGF), transforming growth factor-beta and vascular endothelial growth factor, along with cytokines, recruit fibroblasts, endothelial cells, and keratinocytes to repair damaged blood vessels, these also are antiflammins helping to regulate the inflammatory response.[22,23]

When inflammation goes into remission and immune cells undergo apoptosis, the proliferation phase begins, characterized by tissue granulation, angiogenesis and epithelialization. The remodeling phase occurs once the wound is closed and can last 1 to 2 years or more. During this phase, the provisional matrix is transformed into organized collagen fibers, resulting in complete wound healing.[24] (Figure 1)

Wound healing following injury involves extensive collaboration among various cellular and physiological molecular mechanisms within the skin and its extracellular matrix (ECM), which is highly efficient under normal conditions. However, when repairing deeper layers, efficiency decreases, leading to scar formation with significant loss of the

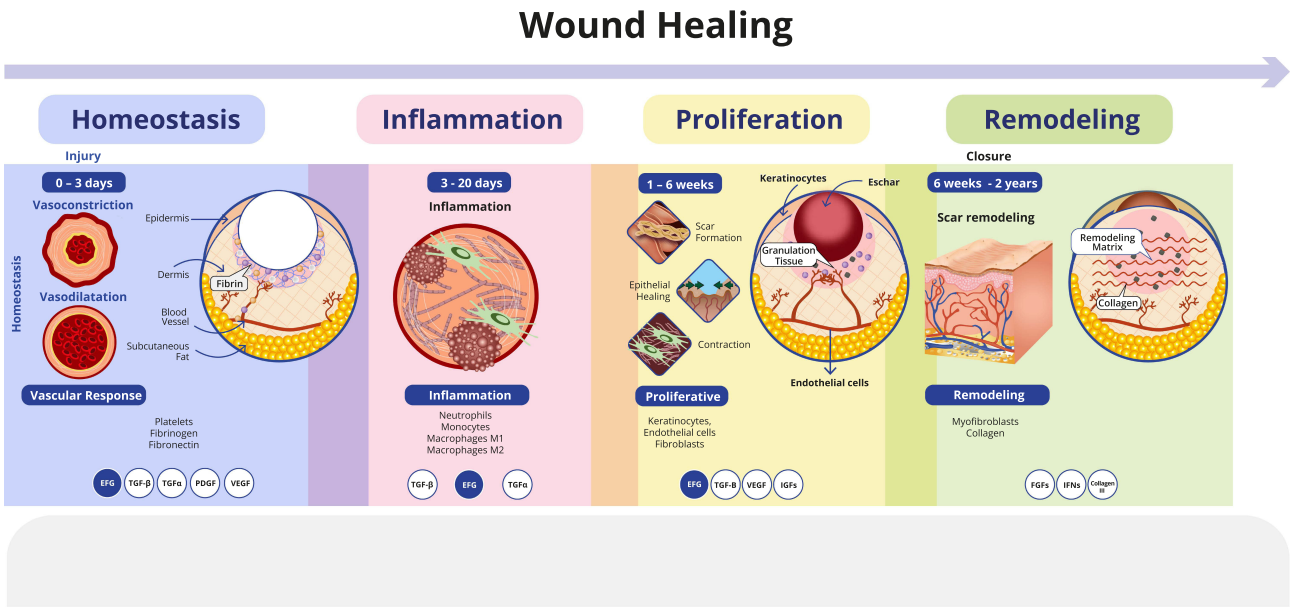

Figure 1 Wound Healing.

original tissue structure and function. When the normal repair response is disrupted there are two possible outcomes: an ulcerative skin defect (chronic ulcer) or excessive scar formation.[25]

Therefore, despite varying causes, the wound healing process is always the same with common characteristics. When this process is disrupted or deregulated, it can lead to non-healing ulcers, which become complex lesions for treatment. Studies have shown that this type of ulcers exhibit continuous competition between inflammatory and anti-inflammatory signals in the tissue and fluid, which leads to an unbalanced environment that makes adequate healing difficult. In the case of diabetic ulcers or venous insufficiency there is an additional predominantly inflammatory component due to the underlying etiology.[26]

In the case of diabetes, exposure to high concentrations of glucose triggers the activation of transcription factors that impose a proinflammatory phenotype, causing important epigenetic changes that generate the continuous activation of nuclear factor-kappaB (NF-kB)-p65 and subsequent inflammatory promoters, leading to a chronic inflammatory state.[27]

This also occurs in venous ulcers secondary to venous insufficiency, where venous hypertension alters endothelial polarity due to hydroelectrolyte alteration produced by intracellular edema in endothelial cells, where the receptors of adhesion molecules are activated, leading to neutrophils and leukocytes adhesion to the venous valves, which impedes oxygen diffusion and growth factor production. This leads to molecular changes that produce an ulcer, resulting in a persistent inflammatory component.[28]

Another phenomenon associated with inflammation that has significant consequences in healing is oxidative stress. This is caused by the excessive and uncontrolled generation of free radicals, which, in the case of diabetic foot ulcer (DFU), can lead to significant damage, including reticular stress, apoptosis, autophagy, interruption of growth factor receptor signaling, orchestration of a program of premature senescence, and proliferative arrest. All these factors interrupt the healing cascade and contribute to the chronicity of wounds. The accumulation of advanced glycation end-products (AGE) or glycoxidation generates similar toxicity, with mechanisms similar to those seen in chronic inflammation, which if amplified or prolonged, the proinflammatory cytokine cascade persists, leading to elevated levels of proteases. In acute wounds, proteases are tightly regulated by their inhibitors; however, in chronic ulcers, protease levels exceed those of their respective inhibitors, leading to the destruction of the extracellular matrix and a decreased availability of growth factors and their receptors.[29]

This proteolytic destruction of the extracellular matrix not only prevents the wound from advancing to the proliferative phase but also attracts more inflammatory cells, thereby amplifying the cycle of inflammation. This pathophysiologically process leads to non-healing-ulcers, characterized by an inability to achieve complete re-epithelialization in the proper temporal sequence of tissue repair. The lesion microenvironment is hostile to the chemical integrity and bioavailability of local growth factors, ultimately impairing their role in the healing process. Some examples of these growth factors are epidermal growth factor (EGF), platelet derived growth factor (PDGF), transforming growth factor beta-1 (TGF-ß 1), and insulin like growth factor I (IGF-1).[30]

Specifically, in diabetic foot wounds, the expression and signaling of EGF and PDGF receptors is also affected. As a result, diabetic wound cells may exhibit reduced tyrosine kinase activity, leading to a loss of growth factor receptor function, predisposing the cells to proliferative arrest and senescence. Wound healing of DFU is hindered by the accumulation of advanced glycation end-products (AGE) that competitively bind to the EGF receptor, thereby preventing EGF binding and perpetuating initial lesion of vascular endothelial cells and fibroblasts.[31]

In chronic ulcers, growth factors are slowly released or stopped, causing a widespread slowdown of the inflammatory process and often causing chronic ulcers to remain in this phase, making their impact on these types of ulcers multifactorial. Therefore, understanding the molecular and physiological mechanisms underlying non-healing wounds highlights the need to transform them into wounds that can heal. This requires restoring the proper balance of cytokines, growth factors, and metabolically competent cells to promote wound healing. Therefore, growth factors play a crucial role in all phases of the wound healing process, produced and secreted by platelets, macrophages and fibroblasts.[31] (Figure 2A and B)

Chronic and complex lower limb ulcers represent a significant challenge for healthcare systems worldwide. However, notable differences in their management exist across regions, influenced by factors such as resource availability, clinical protocols, and healthcare personnel training. For instance, a comparative study between Brazil and Portugal revealed that Portuguese patients exhibited lesions more favorable to healing and received significantly better care than their Brazilian

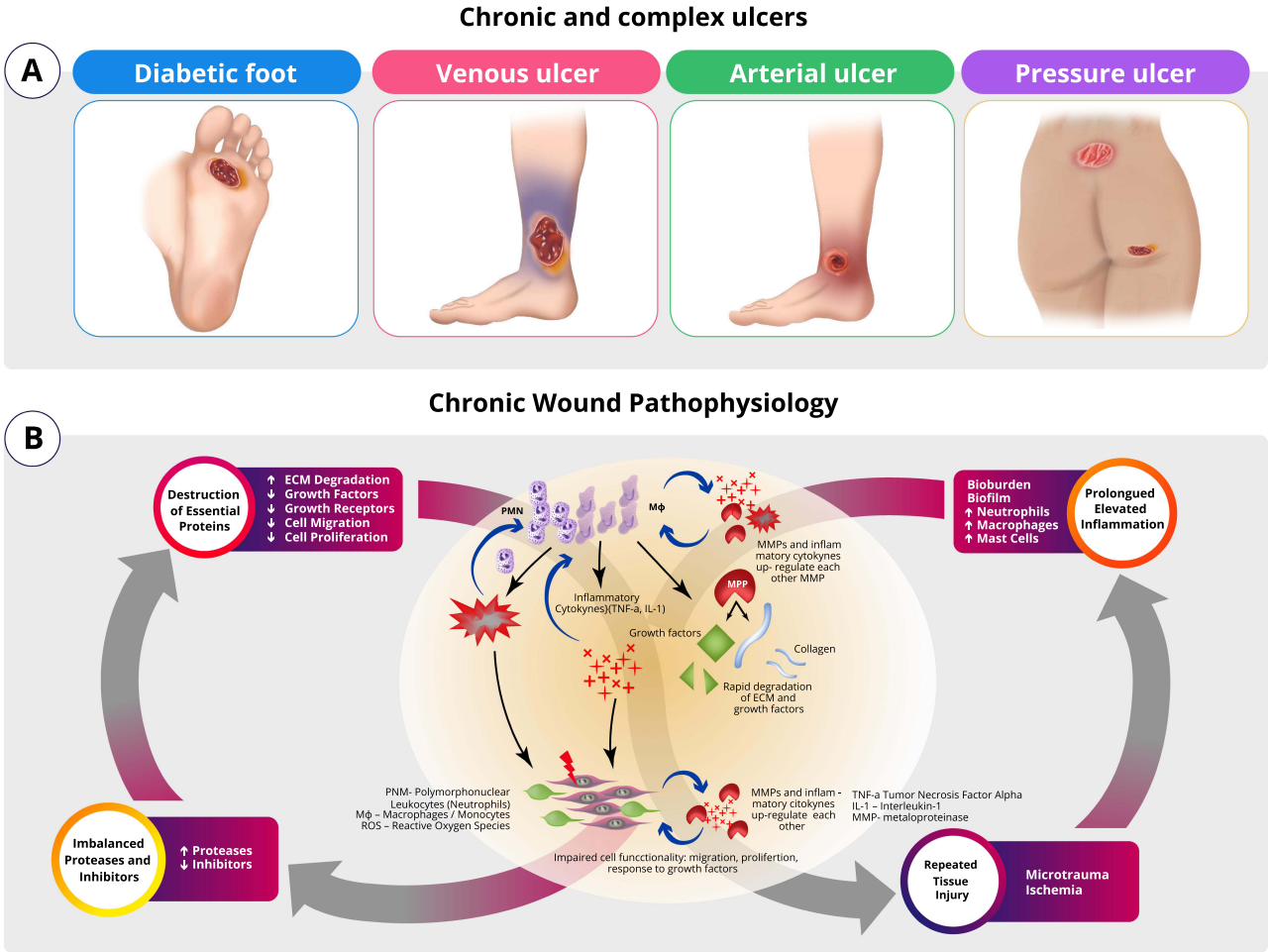

Figure 2 (**A**) Chronic and complex ulcers - Figure 2 (**B**) Chronic Wound Pathophysiology.

counterparts. This was reflected in greater availability of appropriate wound care products, improved access to specialized medical consultations, and the use of complementary diagnostic tools such as Doppler ultrasound, highlighting a disparity in the quality of venous ulcer management between the two countries.[32]

Regarding pressure ulcers in Spain, a high prevalence has been observed in primary care settings, underscoring the need for appropriate preventive and therapeutic strategies.[33] Clinical practice variability is evident when comparing different guidelines and management protocols for pressure ulcers across various regions of Spain, where differences have been identified in ulcer classification systems, recommended treatments, and risk assessment criteria. This heterogeneity may affect treatment efficacy and clinical outcomes, highlighting the importance of establishing standardized protocols based on the most up-to-date scientific evidence.[34]

In the context of diabetic foot ulcers, international guidelines emphasize the importance of comprehensive assessment and a multidisciplinary approach to management. However, the implementation of these recommendations varies across regions. For instance, in some low- and middle-income countries, limited access to advanced technologies and specialized healthcare professionals constrains the application of optimal treatment strategies, which may contribute to higher rates of amputation and mortality.[35]

Basis for the Use of Epidermal Growth Factor (EGF) in the Treatment of Complex Ulcers

As already mentioned, ulcer healing is a complex biological process that is well characterized at a microscopic level. Molecular scaffolding is best known nowadays, indicating that growth factors and their receptors play a major role in

regulating key processes involved in healing. Several studies have shown that growth factors directly regulate important processes such as the chemotactic migration of inflammatory cells, fibroblast mitosis, the growth of keratinocytes and vascular endothelial cells, neovascularization and synthesis of extra-cellular matrix components.[36,37]

The healing environment of the ulcer contains growth factors, and their levels change over the course of the healing process. If growth factors stop working, healing may be affected. In complex ulcer environments, the activity of growth factors is usually low; therefore, their use in the treatment of these wounds will favor their epithelialization.

One of these growth factors is epidermal growth factor (EGF), which is a polypeptide of 53 amino acids weighing 6000 daltons, discovered by Stanley Cohen and Rita Levi in 1962 which led them to receive the Medicine Nobel Prize in 1980. EGF is synthesized by humans and other mammals and produced by different body cells, such as platelets, macrophages and fibroblasts.[38]

It acts by binding to its receptor, inducing tyrosine kinase activity, and initiating intracellular signaling through multiple pathways, including the mitogen/Ras/Raf-activated protein kinase pathway. Cell division and proliferation are facilitated by pathways such as the phosphatidylinositol 3-kinase/Akt pathway, which promotes cell growth, resistance to apoptosis, invasion and migration. The pathway of Janus kinase and signal transduction and transcription activator also intervene in cell survival. These pathways stimulate chemotactic activity, cell proliferation and angiogenesis, ultimately promoting healing.[39] As shown in Figure 3.

EGF has been widely studied for its ability to enhance cell migration, cell mitosis, and extracellular matrix synthesis. It has been used in clinical practice for the treatment of dermal wounds. Studies dating back more than 45 years show that topical application of EGF accelerates wound healing in animal models.

Early publications explored the use of topical preparations. Franklin and Lynch were among the first to demonstrate the efficacy of repeated topical application of EGF in accelerating closure of full-thickness wounds in rabbit ear wounds.[40]

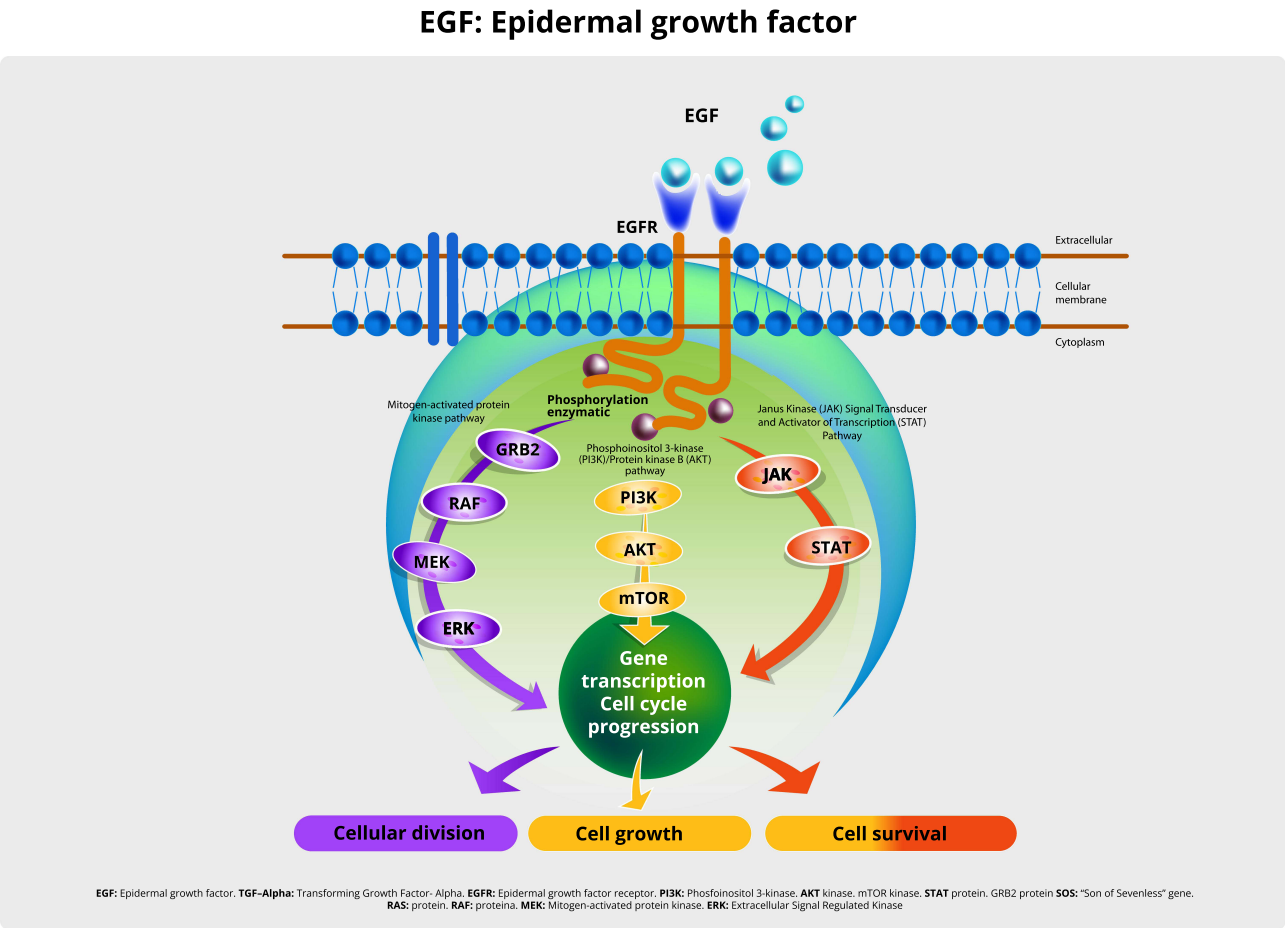

Figure 3 EGF: Epidermal growth factor.

According to these reports, the use of topical EGF treatment in the donor areas of skin grafts produced an average acceleration of 1.5 days in the epithelial regeneration of all patients. The experiments showed that the rate of epithelial regeneration was accelerated by 20% and 30% compared to the control group. Although the clinical significance of such increased healing would be negligible for small wounds, it could provide great clinical benefit for larger ulcers.

However, it was also noted that topical EGF degraded easily in the context of a chronic ulcer, which sometimes made its availability over time difficult.

In the 1990s, the Center for Genetic Engineering and Biotechnology in Havana, Cuba, synthesized a version of this factor produced through recombinant DNA technology using the yeast *Saccharomyces cerevisiae*. This process was advantageous because yeast is not a pathogenic organism for humans, does not produce endotoxins, and has extensive experience in industrial fermentation. In addition, yeast could secrete the mature protein into the culture medium, which greatly facilitates purification.[41]

With this recent research approach, a new drug delivery system was developed to protect and stabilize the protein, placing the great potential and healing effects of EGF at the forefront of research.[42]

By developing this product with intralesional and perilesional routes of administration into the wound, excellent results have been achieved in healing lesions in a short time. EGF, also known as Nepidermin, can penetrate the wound bed, even passing through barriers such as biofilms, reducing degradation and contact with wound exudate. The drug binds to host cell receptors, triggering a biochemical dimerization process through tyrosine kinase and enzymatic phosphorylation, promoting cell proliferation and increasing collagen fibers.¡ In addition, it effectively counteracts the aging of fibroblasts by stimulating their growth, promoting granulation tissue, extracellular matrix formation, and angiogenesis. This supports a structural factor naturally produced by the body but often deficient in chronic and complex ulcers, allowing the inflammatory phase to be unblocked, which is stopped in its progression, thereby achieving wound healing, proving itself as an effective therapy in the management of chronic skin ulcers, shortening the healing process.

The purpose of the following review is to examine the literature on the role of epidermal growth factor (EGF) in the epithelialization of chronic or complex ulcers, and to evaluate the outcomes obtained in their treatment. It is aimed at initiating lines of research in different etiologies of complex ulcers in the intralesional and perilesional application of this molecule.

Methodology

A literature review was conducted to identify studies addressing the objective of this article. The databases consulted included PubMed (Medline), the Cochrane Library, and Google Scholar, using the following search terms: EGF, h-EGF, epidermal growth factor, complex ulcer, pressure ulcers, pressure injury, venous insufficiency ulcer, venous leg ulcer, uses in surgery, oxidative stress, ischemia, and burns (Figure 4). Inclusion criteria encompassed articles published in English and Spanish focusing on the

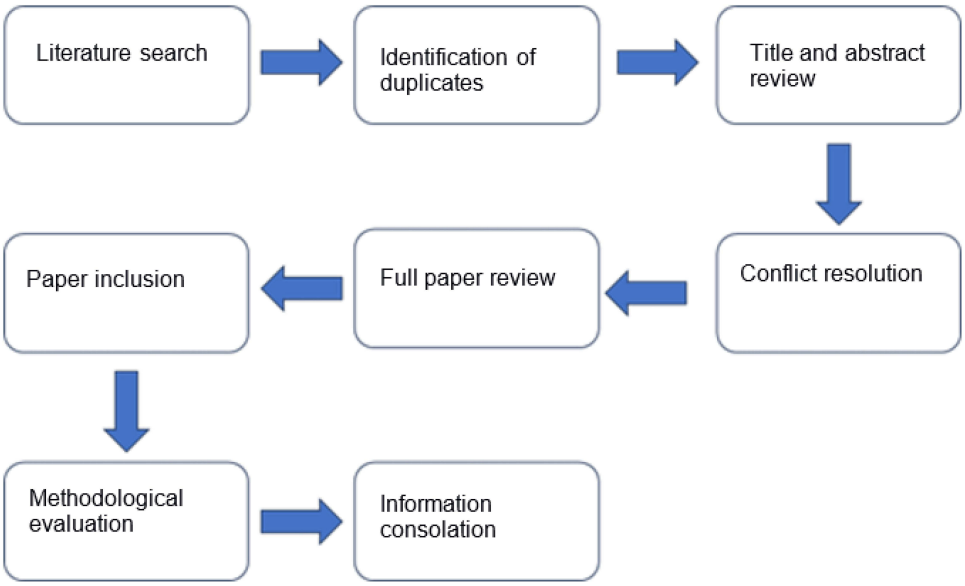

Figure 4 Flowchart for the literature review process and ulcer type organization.

use of EGF. Eligible study designs included systematic reviews, meta-analyses, clinical trials, case series, cohort studies, case reports, as well as prospective and retrospective studies involving intralesional and perilesional applications of EGF in complex ulcers. In the case of diabetic foot ulcers—given that the efficacy of EGF in this indication has been extensively studied and supported by a substantial body of clinical evidence—only meta-analyses, reviews, and studies demonstrating amputation prevention with intralesional or perilesional application were considered. Exclusion criteria included articles on complex ulcers treated with EGF in combination with adjunctive therapies such as dressings. The SANRA guidelines were followed to ensure the quality of this narrative review. However, current evidence remains methodologically heterogeneous regarding the use of growth factors in the treatment of complex ulcers, which limits the feasibility of a rigorous methodological analysis typical of meta-analyses or systematic reviews. Therefore, this publication is presented as a narrative review aiming to provide a broad perspective on the use of EGF for this clinical indication (Figure 4).[43]

Results

After applying the inclusion and exclusion criteria, relevant papers were identified, including comparative retrospective analyses, case report study results, randomized controlled trials (RCTs), and systematic reviews. Forty-five studies were identified by title and abstract. After the different selections, 36 studies were selected for abstract review and after choosing the final articles, 27 articles were read in full text, analyzing their findings (Figure 5).

Amputation

Ekin Ilkeli et al, in 2022, published an observational study aimed at determining the role of recombinant human epidermal growth factor (rhEGF) in the healing and prevention of amputation in DFUs, conducted between November 2018 and

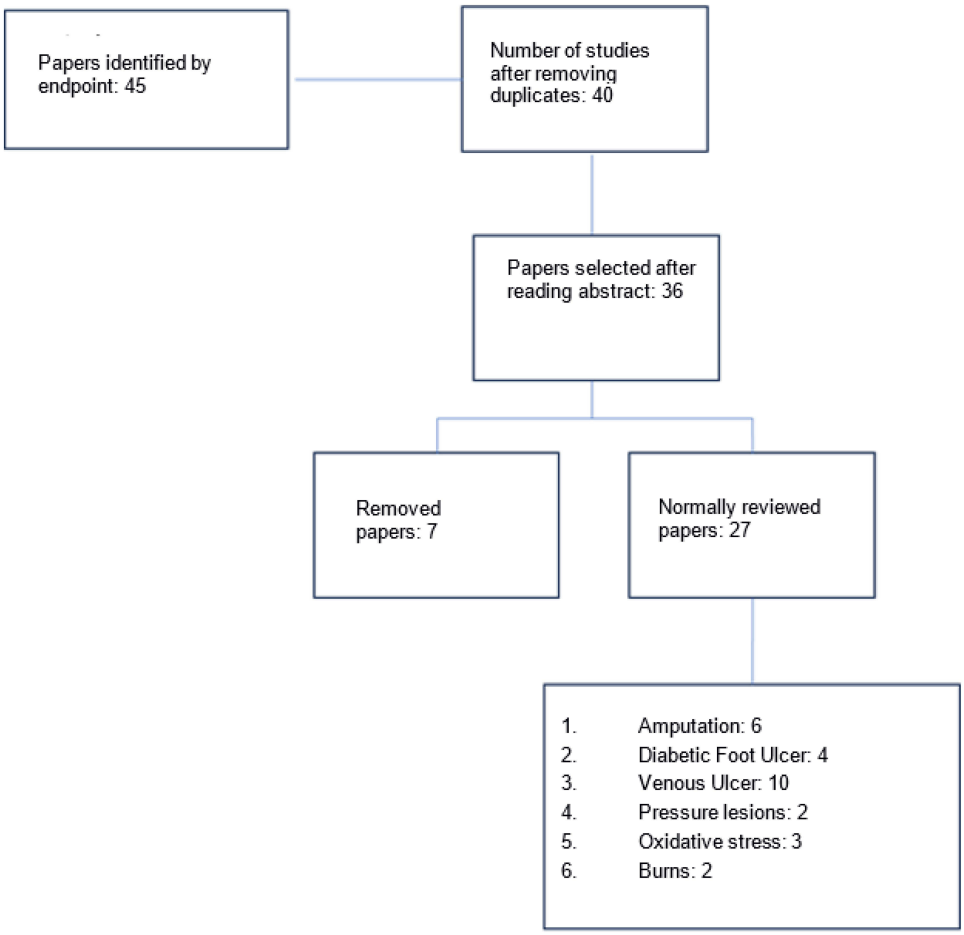

Figure 5 Literature review perspective.

September 2019 with 58 patients. Granulation was achieved in 93.1% of patients, full recovery in 94.1% of patients, and lower extremity amputation was performed in two (3.4%) subjects. Concluding that rhEGF is highly effective for the treatment of diabetic foot ulcers and the prevention of extremity amputation. Ömer Arda Çetinkaya et al, in 2020, aimed to investigate the effectiveness of EGF in preventing major extremity amputation. Thirty-three patients were treated between January 2013 and January 2017, with the objective of preventing major amputations within the following 12 months. Results for the 30 patients at 12 months of treatment included one major amputation and seven minor amputations. The study concluded that the intralesional application of EGF shows positive and promising results, effectively protecting the limb from amputation.

Murat Kahraman et al, in a 2019 study of long-term outcomes following intralesional application of rhEGF in 34 patients with DFU, wound closure was achieved in 33 of the 36 (91.7%) lesions, tissue granulation in 29 (87.9%), after 5 years of follow-up. Of the remaining 29 patients, 27 had no ulcers, 2 patients (6.9%) required toe amputation due to ischemic necrosis, concluding that full wound healing and low recurrence and amputation rates could be obtained by adding EGF to the standard treatment protocol. In 2009, Montequin et al conducted a pilot study with 20 patients suffering from diabetic foot ulcers (DFUs) that had persisted for more than 4 weeks. The patients were treated with intralesional rhEGF, resulting in granulation in all 20 patients, with ulcers closing in 17 (85%), and no amputations reported. In a 2007 study, Montequin et al evaluated doses of 25 mcg and 75 mcg in 41 patients, with 23 receiving the 75-mcg dose. Of this group, 83% achieved granulation, and 13 patients (56%) healed completely. After 1 year of follow-up, only one patient was amputated, and this case was not in the 75-mcg group. The findings concluded that local injection of rhEGF significantly improves the healing of advanced DFUs and reduces the risk of severe amputation. In 2006, Berlanga et al conducted a study in 29 patients with DFUs and a high risk of amputation, with a one-year follow-up. The study showed 86% granulation and amputation was not needed in 58.6%. Preliminary evidence suggests that intralesional EGF infiltrations may be effective in reducing lower extremity amputation in diabetic patients. (Table 1)

Table 1 Characteristics of the Studies Included in the Analysis - Amputation

Study Title	Authors / Year of the Study	Reference Number
Intralesional Epidermal Growth Factor for Diabetic Foot Ulcers.	Ilkeli E., Berna F., Demircan G., Cemal A, Hakan A, Uysal A, Kanko (2022)	[44]
Intralesional Epidermal Growth Factor application is a potential therapeutic strategy to improve diabetic foot ulcer healing and prevent amputation	Çetinkaya Ö, Utku S., Erzincan B., Hazır B., Uncu H. (2020)	[45]
The Long-Term Outcomes Following the Application of Intralesional Epidermal Growth Factor in Patients With Diabetic Foot Ulcers	Kahraman M., Misir A., Bilge T., Ozcamdalli M., Uzun E., Mutlu M. (2019)	[46]
Intralesional administration of epidermal growth factor-based formulation (Heberprot-P) in chronic diabetic foot ulcer: treatment up to complete wound closure	Montequin F., Betancourt B., Leyva-Gonzalez G., Mola E., Galan K., Ramyrez M., Bermúdez R, Rosales F., Garcia I., Berlanga j., Silva R., Marianela R., Siverio G., Martinez L. (2009)	[47]
Intralesional injections of Citoprot-P (recombinant human epidermal growth factor) in advanced diabetic foot ulcers with risk of amputation	José Fernandez Montequin, Ena Infante-Cristiá, Carmen Valenzuela Silva, Neobalis Franco-Perez, William Savigne-Gutierrez, Heriberto Artaza-Sanz, Lourdes Morejón Vega, Cecilio González Benavides, Osvaldo Eliseo Musenden, Elizeth García Iglesias, Jorge Berlanga Acosta, Ricardo Silva Rodríguez, Blas Y Betancourt, Pedro A López Saura (2007)	[48]
Epidermal growth factor intralesional infiltrations can prevent amputation in patients with advanced diabetic foot wounds	Jorge Berlanga Acosta, William Savigne, Calixto Valdez, Neobalis Franco, Jose S Alba, Amaurys del Rio, Pedro López-Saura, Gerardo Guillén, Ernesto Lopez, Luís Herrera, José Férnandez Montequín (2006)	[49]

Diabetic Foot Ulcer

Rahim et al in 2023 made a meta-analysis to compare the effectiveness of EGF and placebo in DFUs. Eight RCTs were found that included 620 patients (337 in the EGF group, 283 in the placebo group). After 4 weeks of treatment, in the placebo group it was 17%, while in the EGF group it was 34%, concluding that EGF significantly promotes wound healing for DFUs. Ding-Yun Zhao et al (2020) conducted a meta-analysis reviewing RCTs up to January 30, 2020. The analysis included 9 trials with a total of 720 participants, evaluating healing time and routes of administrations. EGF provided 2.7 times more full healing times, and shorter healing time −14.10 days. Subgroup analysis showed that topical application was superior to intralesional injection, but this may be due to the different severity of the ulcer, which was lower in topical application.

In 2019, Bui TQ et al evaluated the effect of rhEGF on the healing of DFUs through a review of six studies involving 530 patients conducted in Vietnam and Hungary. A total of six studies in 530 patients were analyzed. The intralesional and topical route of administration was 4.5 versus 3.5, respectively. The use of rhEGF along with standard ulcer care significantly facilitates the healing rate compared to placebo control. Elisavet et al reviewed the routes of administration of rhEGF, including topical or intralesional and perilesional application, concluding that the latter has better availability in the deep layers of the wound, but pain at the injection site is a common complaint.[50] (Table 2)

Venous Ulcer

Colombia has been a pioneer in the intralesional and perilesional use of rhEGF in venous ulcers and in the production of literature demonstrating that this factor shortens healing time in this type of wounds.

In 2024, Cacua et al published a study on the impact of rhEGF treatment on a health system like the Colombian health system, compared to other local therapies such as apostates and other devices. The study found that rhEGF and hydrogels significantly reduced healing time. This research extended their 2022 study, which included 105 patients with 139 ulcers. The 2022 study found that patients under private regimes had 5.8 times higher probability of ulcer closure compared to those under government regimes.

In 2023, Cacua et al met as a group of expert vascular surgeons from different countries in America such as the United States, Mexico, Cuba, Colombia, Chile, and Uruguay and generated 12 recommendations for the use of rhEGF, for local treatment and to generate clinical studies in venous ulcers.

In 2022, a systematic review and meta-analysis of randomized trials was performed. Of the 1645 papers, 13 trials were included, concluding that growth factors have a beneficial effect on the full healing of venous ulcer wounds, increasing the percentage reduction in the wound area.

In 2021, Cacua et al published a retrospective comparative study with 48 patients, with 24 patients treated with rhEGF and 24 patients treated with hydrocolloids, along with compression therapy in both groups. The study found that 71% of the patients achieved full epithelialization with rhEGF within 8 weeks, compared to an average of 29.5 weeks with the other therapy, and patients with rhEGF were 3.4 times more likely to achieve closure in 8 weeks than those treated with hydrocolloids.

Table 2 Characteristics of the Studies Included in the Analysis: Only Meta-Analyses

Study Title	Authors / Year of the Study	Reference Number
Epidermal growth factor outperforms placebo in the treatment of diabetic foot ulcer: a meta-analysis.	Fazal Rahim, Xie Yan, Jawad Ali Shah, Nida Bibi, Zafar Ullah Khan, Shah Nawaz, Yao Ming (2023)	[51]
Efficacy and safety of recombinant human epidermal growth factor for diabetic foot ulcers: A systematic review and meta-analysis of randomised controlled trials	Ding-Yun Zhao, Ya-Na Su, Yong-Hong Li, Tian-Qi Yu, Jing Li, Chong-Qi Tu (2020)	[52]
Epidermal Growth Factor is Effective in the Treatment of Diabetic Foot Ulcers: Meta-Analysis and Systematic Review	Thien Quoc Bui, Quoc Van Phu Bui, Dávid Németh, Péter Hegyi, Zsolt Szakács, Zoltán Rumbus, Barbara Tóth, Gabriella Emri, Andrea Párniczky, Patricia Sarlós and Orsolya Varga (2019)	[53]
Epidermal Growth Factor in the Treatment of Diabetic Foot Ulcers: An Update	Elisavet K. Tiaka, Nikolaos Papanas, Anastassios C. Manolakis, George S. Georgiadis (2015)	[50]

More case report-type studies or narrative reviews have been observed, such as 2020 review that summarized the experience of using rhEGF for intralesional and perilesional application in Colombia, and its positive results was published. Later, in this same year, Dr. Chun Mao's group published a clinical guide on the use of growth factors based on the literature suggesting that EGF can promote the healing of various types of skin wounds. Although this guideline's recommendation for this factor is low, it is becoming more visible again and its evidence in the treatment of venous ulcers is increasing in quality. It must be considered that this study includes EGF in lyophilized solution.

Other case reports, such as Daza et al (2019), reported the case of 2 diabetic foot ulcers and an ulcer of venous origin, which epithelialized with intralesional and perilesional application within 8 weeks. In this same year, the Brazilian group led by Dr. Carvahlo carried out a systematic review and meta-analysis on the use of growth factors in venous ulcers with better results: Platelet Rich Plasma and Epidermal Growth Factor. It should be noted that the use of EGF was administered topically.

In 2019, Cacua et al reported a series of cases involving 28 patients with 35 chronic venous ulcers. The results showed 69% of epithelialization and 100% of granulation. Esquirol et al (2018) reported on 77 patients treated with rhEGF for various etiologies, including DFUs, venous ulcers, surgical ulcers, and burns. They conclude that topical rhEGF in individualized formulation (composition) appears to show efficacy, comfort, and tolerability. (Table 3)

Table 3 Characteristics of the Studies Included in the Analysis - Venous Ulcer

Study Title	Authors / Year of the Study	Reference Number
Effectiveness of the Use of the Human Recombinant Epidermal Growth Factor in the Subsidized Regime vs The Contributive Regime in Patients with Venous Ulcers in Bogotá	Maria Teresa Cacua Sanchez, Gustavo Buenahora, Carlos Alberto Carrillo Bravo (2024)	[54]
Use of Intralesional and Perilesional Human Recombinant Epidermal Growth Factor (rhEGF)in the Local Treatment of Venous Ulcer – Review Article – Expert Recommendation	Maria Teresa Cacua Sanchez, Lina M Vargas Abello, Álvaro Orrego, Paola Ortiz, Héctor Segura, Jhon Jairo Berrio Caicedo, Luz Marina Zuluaga, José Ordoñez, José Ignacio Fernández Montequin, Jorge Ulloa. (2923)	[55]
Socio-Demographic Characteristics and Associated Factors of Morbidity in Patients with Venous Ulcers Treated in Two Institutions of Contributive and Subsidized Regime in Colombia: Retrospective, Multicenter, Observational Study	Maria Teresa Cacua Sanchez, Gustavo Buenahora (2022)	[56]
Growth factors for treating chronic venous leg ulcers: A systematic review and meta-analysis	Yung Lee, Michael H Lee, Steven A Phillips, Michael C Stacey (2022)	[57]
Efficacy of recombinant human epidermal growth factor plus compression therapy versus hydrocolloid dressing plus compression therapy in the treatment of venous leg ulcers	Maria Teresa Cacua Sanchez, Luis Fernando Giraldo, Jhon Alejandro Diaz (2021)	[58]
Use of Human Recombinant Epidermal Growth Factor in Chronic Wounds: Experience in Colombia - Review Article	Maria Teresa Cacua Sanchez (2020)	[59]
Clinical practice guideline for the use of growth factors in wound healing: A systematic review and meta-analysis of randomized controlled trials	Chun-mao Han, Biao Cheng, PanWu (2020)	[60]
A new alternative in the management of complex vascular ulcer with recombinant epidermal growth factor, Epiprot® (NEPIDERMIN).	Daza Arias Julio, García Dávila Ricardo, Lozano Herrera Edward, Tolstano Axel Adonai	[61]
Experience with the use of perilesional and intralesional recombinant human epidermal growth factor (Nepidermin) in the treatment of patients with chronic venous ulcers.	Maria Teresa Cacua Sanchez, Luis Fernando Giraldo (2019)	[62]
Human recombinant epidermal growth factor in skin lesions: 77 cases in EPItelizando project	Jordi Esquirol Caussa, Elisabeth Herrero-Vila (2018)	[63]

Pressure Lesions

Meng Wei Ge et al generated a meta-analysis to evaluate rhEGF efficacy in pressure lesions, ratio, and healing time, with 16 RCTs, for a total of 1206 patients. The total effective healing rate in the rhEGF group was 97.18%, which was significantly higher than 83.38% in the control group. The ratio of full healing in the rhEGF group was 73.30%, greater than 39.52% in the control group. The healing time with rhEGF was shorter.

In 2011, Montequin et al published a series of cases that showed the benefit obtained in healing PL, were the observed that in 2 patients with 4 years of chronicity, healing was achieved within 8 weeks and 6 weeks, respectively. Another patient with Fournier's Gangrene epithelialized with 18 applications of rhEGF. (Table 4)

Oxidative Stress

In 2020, Ojalvo et al determined the molecular profile of patients with DFUs and the systemic effects of treatment with intralesional rhEGF, measuring redox balance markers, advanced glycation products (AGE), extracellular matrix factors (ECM), and pro-inflammatory markers. Thirteen patients with DFUs were treated compared to diabetics without ulcers (compensated and uncompensated), and non-diabetic individuals. The results showed that patients with DFUs had a very altered biochemical profile, with high oxidative stress and low antioxidant reserves, increased glycosylation and matrix metalloproteases (MMP), unlike the other groups. The intralesional administration of EGF was associated with a significant recovery of the parameters studied and the systemic attenuation of several pro-inflammatory markers, concluding that the results indicate that intralesional infiltration with EGF translates into systemic antioxidant, anti-inflammatory, anti-degrading, and anti-AGE effects.

In 2019, Ojalvo and Berlanga suggested that EGF has emerged as a therapeutic alternative for DFUs reaching sensitive cells while avoiding the harmful effect of proteases and biofilm on the wound surface. This study shows that intralesional EGF therapy is associated with systemic attenuation of marker proinflammatory effects along with recovery of redox balance. In a study involving 11 diabetic patients, evaluations were conducted before treatment and 3 weeks later. The study measured plasma levels of proinflammatory markers, redox balance, and glycation markers. Results showed a significant reduction in proinflammatory markers, an improvement in redox balance, and a notable increase in soluble receptor for advanced glycation end-products.

Ojalvo et al (2016) showed intralesional infiltration of rhEGF as an alternative to reduce the proteolytic effect of the environment in the wound center. This study characterized the response of patients with DFUs to treatment with rhEGF in markers of redox status. Patients with DFUs before and after starting treatment with rhEGF, diabetes-compensated and non-compensated, and non-diabetic subjects were included. Administration was associated with significant recovery from oxidative stress and antioxidant reserve markers. (Table 5)

Burns

These two topics were unified since they are typical of the specialty of plastic surgery. In the 2024 article by Espitaleta et al, the study explores the integration of recombinant rhEGF with comprehensive and multidisciplinary burn treatment. The findings indicate that rhEGF application led to rapid wound revitalization and favorable outcomes, including improvements in bone resorption. The study concludes that rhEGF could be a valuable therapeutic strategy for enhancing both the aesthetic and functional results of electrical burns. This confirms what

Table 4 Characteristics of the Studies Included in the Analysis - Pressure Lesions

Study Title	Authors / Year of the Study	Reference Number
Efficacy of Recombinant Human EpidermalGrowth Factor in Pressure Injury Healing:Evidence from Chinese Randomized ControlledTrials	Meng-Wei Ge, Fei-Hong Hu, Yi-Jie Jia, Wen Tang, Wan-Qing Zhang, Hong-Lin Chen (2024)	[64]
Heberprot P as a Therapeutic Indication in Treatment Healing of Pressure Ulcers	Fernández Montequin J, Sancho Soutelo N. Fleitas Pérez E, Santiesteban Bonaechea LI	[65]

Table 5 Characteristics of the Studies Included in the Analysis - Oxidative Stress

Study Title	Authors / Year of the Study	Reference Number
Systemic effects of intralesional treatment with growth factor epidermal (Heberprot-P) in patients with diabetic foot ulcers	Ariana García Ojalvo, Jorge Berlanga Acosta, Yssel Mendoza Marí, Maday Fernández Mayola, Mónica Béquet Romero, Calixto Valdés Pérez, William Savigne Gutiérrez, Alain Figueroa Martínez, Ileydis Iglesias Marichal, Eduardo Álvarez Seijas, Amirelia Fabelo Martínez, Gerardo Guillén Nieto. (2022)	[66]
Systemic translation of locally infiltrated epidermal growth factor in diabetic lower extremity wounds	Ariana García-Ojalvo, Jorge Berlanga Acosta, Alain Figueroa Martínez, Mónica Béquet Romero, Yssel Mendoza Marí, Maday Fernández Mayola, Amirelia Fabelo-Martínez, Gerardo Guillén Nieto.	[67]
Healing enhancement of diabetic wounds by locally infiltrated epidermal growth factor is associated with systemic oxidative stress reduction	Ariana García Ojalvo, Jorge Berlanga Acosta, Yssel Mendoza Marí, Maday Fernández Mayola, CalixtoValdés Pérez, William Savigne Gutiérrez, Ileydis Iglesias Marichal, Eduardo Álvarez Seijas, AliciaMolina Kautzman, Angélica Estrada Pacheco, & David G. Armstrong	[68]

Table 6 Characteristics of the Studies Included in the Analysis - Burns

Study Title	Authors / Year of the Study	Reference Number
EGF in the treatment of electrical burns and the decrease of bone resorption	Espitaleta Omaira, Román Carlos, Gaviria N. Ángela María, Carrillo B. Carlos Alberto	[69]
Electrical burn: case report, multidisciplinary treatment and effectiveness of treatment with recombinant epidermal growth factor.	Espitaleta Omaira, Montoya Mario, Barranco Luis	[70]

was found by Espitaleta et al (2018) in a previous case report on this same pathology: EGF improves aesthetic results in patients with electrical burns in addition to functional aspects, with rapid epithelialization and a favorable evolution (Table 6).

Discussion

All current guidelines and consensus reviews regarding the treatment of complex ulcers support that these wounds should be treated initially with standard wound care principles. In most cases, these basic ulcer care principles should be carried out before considering the use of more advanced therapies. Currently, most ulcer care protocols advocate the use of such standard measures for an initial period of 4 weeks, after which an evaluation of wound surface reduction should be performed, since ulcers that do not heal within 4 weeks are associated with worse outcomes, including amputation.

A 50% reduction in ulcer area at 4 weeks has been widely accepted and confirmed as a strong indicator to predict healing at 3 months. Based on this premise, wounds that do not achieve the 50% area reduction at this time should be reevaluated and potentially considered for more advanced therapies.[71]

The literature suggests that 50–70% of these wounds will remain active at 20 weeks despite standard treatment, underscoring the importance of identifying factors that may delay the healing process during initial evaluation and determining early start of these advanced therapies.

A study was conducted in patients with DFUs and venous ulcers to determine whether healing rates were reliable early predictors of ulcer closure. The study evaluated 306 venous ulcers and 241 DFUs, finding that ulcer margin progression, initial healing rate, percentage reduction in wound surface area, and wound healing paths were potent

predictors of full ulcer healing ulcer in 12 weeks. Wounds with poor healing progression by these criteria at 4 weeks were very likely to remain unhealed after an additional 8 weeks of treatment.[72]

However, recent publications, such as the 2017 paper titled "Proactive and Early Aggressive Management of Wounds: A change in strategy", written by a multidisciplinary group of global experts in wound care led by Dr. Gregory Shultz and Dr. Gregory Bon present an algorithm that represents a change in strategy towards the aggressive and early treatment of ulcers, where they advocate breaking the pathophysiological cycle of an existing chronic ulcer, essential to promote early healing. The consensus panel recommends an early treatment strategy with advanced ulcer therapies for high-risk patients.[73]

Panel members use this strategy for all patients with acute wounds or chronic ulcers in their own consultations, indicating the early use of advanced therapies to shorten the healing time of these ulcers, and in patients with risk factors and acute ulcers, prevent these lesions from quickly becoming chronic, minimizing the risk of these lesions do not progress to epithelialization.

Mesmer's study of immunohistochemistry and skin molecular biology in patients with chronic venous insufficiency and venous ulcers revealed that EGF receptors were present in greater numbers in both healthy and hyperproliferative epidermis. The significant localization of epidermal growth factor receptors (EGFr) in the epidermis affected by stasis dermatitis, and lipodermatosclerosis suggests that the receptors necessary for EGF and its ligands are expressed in the keratinocyte population with an amplified proliferation rate during these phases of the CVI. However, there was a lack of EGFr expression at the wound edges of the ulcers due to decreased keratinocyte proliferation and motility, which could be responsible for the poor healing properties of venous ulcers on the legs.[74]

Another risk factor is oxidative stress, where it has been observed that, in patients with diabetic foot ulcers, they show significantly higher levels of markers of oxidative capacity and advanced protein oxidation products, compared to other experimental groups, where the application of rhEGF shows a significant reduction compared to the baseline value.

Another important risk factor within the chronicity of an ulcer is inflammation. In vitro studies have shown that EGF promotes mitosis and glycolysis and induces the migration of inflammatory cells out of the ulcer, leading to improvement of the tissue micro-environment.[75,76]

All this has led to this medication being included in the clinical practice guidelines for the diagnosis and treatment of patients with complicated diabetic foot in Colombia, in which multiple scientific societies participated suggesting the use of rhEGF to reduce the healing time of complicated diabetic foot ulcers.[77]

Regarding cost-effectiveness studies on the use of EGF in diabetic foot, several studies have been published. For instance, in 2014, a paper from Mexico demonstrated an economic evaluation of cost-utility and cost-effectiveness using a Markov model. The analysis showed that patients treated with recombinant human epidermal growth factor had 1.58 months of adjusted quality life span than those treated with standard therapy. Also, the use of recombinant human epidermal growth factor reduced amputations by 11.8% during the period analyzed.[78]

In Colombia, the Markov model was also used to evaluate the profitability of rhEGF treatment of DFUs in 2018. Weekly treatment cycles were evaluated over a 5-year period. The treatment produced 39 fewer amputations than conventional treatment in a cohort of 100 patients and provided 0.65 quality-adjusted life years for an average patient. The cost-effectiveness relationship turned out to be lower than the threshold established for Colombia.[79]

In 2021, Osorio et al conducted a study on the cost-effectiveness of EGF vs negative pressure therapy (NPT), determining that the therapeutic alternative of rhEGF is a strategy where its average cost is lower compared to the NPT alternative. Similarly, it provides more QALY for these patients (2.64 compared to 2.39). This indicates that an additional QALY has a better cost-effectiveness ratio in the case of growth factor. Concluding that the use of growth factor is a feasible option for the management of diabetic foot ulcers of Wagner grade 3 or 4 due to the greater effectiveness and lower cost compared to TPN.[80]

In May 2024, Cacua et al conducted a cost-effectiveness study in patients with venous ulcers vs use of hydrocolloid. A Markov model was used to determine cost-effectiveness over a period of 5 years, concluding that although rhEGF is more expensive per unit than hydrocolloids, it was shown to be effective for healing ulcers in 8 to 12 weeks, even in complex cases. Hydrocolloids, on the other hand, typically require an average of 29.5 weeks and ≤46 weeks in complex cases. Despite the cost, rhEGF is more cost-effective because it achieves results comparable to those of therapy with hydrocolloids at a lower cost per additional quality-adjusted year of life.[81]

Conclusion

The pathophysiology of chronic ulcers, combined with advances in molecular biology and technology, along with the interest in identifying early markers related to delayed healing, have led to the development of a wide range of advanced modalities that hold potential to positively influence the molecular events involved in epithelialization. One such modality is the use of EGF, which has been studied for over 45 years. Currently, its intra- and perilesional application provides greater stability to the molecule, enhancing its bioavailability in the wound, preventing denaturation, and yielding more significant results compared to other application methods.

Studies and increasingly robust literature worldwide have demonstrated its significant potential as an adjuvant therapy in reducing the healing time of chronic lesions. Intralesional administration has shown high rates of granulation and epithelialization, making it more effective and bioavailable in the management of chronic ulcer. This cost-effective technological product has made, and will continue to make, a positive impact on patients suffering from these lesions.

Disclosure

The authors report no conflicts of interest in this work.

References

1. Ferreira MC, Tuma Júnior P, Carvalho VF, Kamamoto F. Complex wounds. *Clinics*. 2006;61(6):571–578. doi:10.1590/S1807-59322006000600014
2. National Institutes of Health. Definition of wounds [Internet]. Bethesda (MD): National Cancer Institute; 2024. Available from: https://www.cancer.gov/espanol/publicaciones/diccionarios/diccionario-cancer/def/herida. Accessed April 7, 2025.
3. Clínica Universidad de Navarra. Medical dictionary: ulcer [Internet]. Pamplona (ES): Clínica Universidad de Navarra; 2024 Available from: https://www.cun.es/diccionario-medico/terminos/ulcera. Accessed April 7, 2025.
4. Tricco AC, Antony J, Vafaei A, et al. Seeking effective interventions to treat complex wounds: an overview of systematic reviews. *BMC Med*. 2015;13:89. doi:10.1186/s12916-015-0288-5
5. European Wound Management Association (EWMA). *Position Document: Hard-to-Heal Wounds – A Holistic Approach*. London: MEP Ltd; 2008.
6. Rayner R, Carville K, Keaton J, Prentice J, Santamaria XN. Leg ulcers: atypical presentations and associated co-morbidities. *Wound Pract Res*. 2009;17(4):168–185.
7. Sasanka CS. Venous ulcers of the lower limb: where do we stand? *Indian J Plast Surg*. 2012;45(2):266–274. doi:10.4103/0970-0358.101294
8. Velasco M. Diagnostic and therapeutic aspects of leg ulcers. *Actas Dermosifiliogr*. 2011;102(10):780–790. doi:10.1016/j.ad.2011.05.005
9. Sen CK, Gordillo GM, Roy S, et al. Human skin wounds: a major snowballing threat to public health and the economy. *Wound Repair Regen*. 2009;17(6):763–771. doi:10.1111/j.1524-475X.2009.00543.x
10. Uwaezuoke PD, Nnadozie UU, Ndukwu CU. Prevalence and risk factors associated with amputation in patients with diabetic foot ulcers. *Niger J Clin Pract*. 2018;21(6):781–787.
11. Frölke JPM, Rommers GMC, de Boer AW, Groenveld TD, Leijendekkers RA. Epidemiology of limb amputations and prosthesis use during the COVID-19 pandemic in the Netherlands. *J Rehabil Med*. 2021;53(1):jrm00159. doi:10.2340/16501977-2788
12. Zhang P, Lu J, Jing Y, Tang S, Zhu D, Bi Y. Global epidemiology of diabetic foot ulceration: a systematic review and meta-analysis. *Ann Med*. 2017;49(2):106–116. doi:10.1080/07853890.2016.1231932
13. Oliver TI, Mutluoglu M. Diabetic foot ulcer. In: statPearls [Internet]. Treasure Island (FL): StatPearls Publishing; 2023. Available from: https://www.ncbi.nlm.nih.gov/books/NBK537328/. Accessed April 7, 2025.
14. Armstrong DG, Wrobel J, Robbins JM. Guest editorial: are diabetes-related wounds and amputations worse than cancer? *Int Wound J*. 2007;4(4):286–287. doi:10.1111/j.1742-481X.2007.00392.x
15. Icks A, Genz J, Haastert B, Giani G, Glaeske G, Hoffmann F. Time-dependent impact of diabetes on mortality in patients after major lower extremity amputation. *Diabetes Care*. 2011;34(6):1350–1354. doi:10.2337/dc10-2341
16. Kerr M. Foot care for people with diabetes: the economic case for change [Internet]. NHS Diabetes; 2012. Available from: http://www.diabetes.org.uk/Documents/nhs-diabetes/footcare/footcare-for-people-with-diabetes.pdf. Accessed June 10, 2025.
17. Agale SV. Chronic leg ulcers: epidemiology, aetiopathogenesis, and management. *Ulcers*. 2013;2013:413604. doi:10.1155/2013/413604
18. Berenguer-Perez M, Lopez-Casanova P, Sarabia-Lavin R, Gonzalez de la Torre H, Verdu-Soriano J. Epidemiology of venous leg ulcers in primary health care: incidence and prevalence in a health centre—a time series study (2010–2014). *Int Wound J*. 2019;16(1):256–265. doi:10.1111/iwj.13026
19. Finlayson K, Wu ML, Edwards HE. Identifying risk factors and protective factors for venous leg ulcer recurrence using a theoretical approach: a longitudinal study. *Int J Nurs Stud*. 2015;52(6):1042–1051. doi:10.1016/j.ijnurstu.2015.02.016
20. Nettel F, Rodriguez N, Nigro J, et al. First Latin American consensus on venous ulcers. *Mex J Angiol*. 2013;41(3):95–126.
21. Pérez LA, Leyton L, Valdivia A. Thy-1 (CD90), integrins and syndecan 4 are key regulators of skin wound healing. *Front Cell Dev Biol*. 2022;10:810474. doi:10.3389/fcell.2022.810474
22. Schultz GS, Chin GA, Moldawer L, et al. Principles of wound healing. In: Fitridge R, Thompson M, editors. *Mechanisms of Vascular Disease: A Reference Book for Vascular Specialists [Internet]*. Adelaide (AU): University of Adelaide Press; 2011.
23. Sousa AB, Barbosa JN. The role of neutrophils in biomaterial-based tissue repair—shifting paradigms. *J Funct Biomater*. 2023;14(6):327. doi:10.3390/jfb14060327
24. Landén NX, Li D, Ståhle M. Transition from inflammation to proliferation: a critical step during wound healing. *Cell Mol Life Sci*. 2016;73(20):3861–3885. doi:10.1007/s00018-016-2268-0

25. Gibson D, Cullen B, Legerstee R, Harding KG, Schultz G. MMPs made easy. *Wounds*. 2009.
26. Eming SA, Martin P, Tomic-Canic M. Wound repair and regeneration: mechanisms, signaling, and translation. *Sci Transl Med*. 2014;6(265):265sr6. doi:10.1126/scitranslmed.3009337
27. Roberts AC, Porter KE. Cellular and molecular mechanisms of endothelial dysfunction in diabetes. *Diab Vasc Dis Res*. 2013;10(6):472–482. doi:10.1177/1479164113500680
28. Raffetto JD, Ligi D, Maniscalco R, Khalil RA, Mannello F. Why venous leg ulcers have difficulty healing: overview on pathophysiology, clinical consequences, and treatment. *J Clin Med*. 2020;10(1):29. doi:10.3390/jcm10010029
29. Frykberg RG, Banks J. Challenges in the treatment of chronic wounds. *Adv Wound Care*. 2015;4(9):560–582. doi:10.1089/wound.2015.0635
30. Berlanga-Acosta J, Fernández-Montequín J, Valdés-Pérez C, et al. Diabetic foot ulcers and epidermal growth factor: revisiting the local delivery route for a successful outcome. *Biomed Res Int*. 2017;2017:2923759. doi:10.1155/2017/2923759
31. Zheng SY, Wan XX, Kambey PA, et al. Therapeutic role of growth factors in treating diabetic wound. *World J Diabet*. 2023;14(4):364–395. doi:10.4239/wjd.v14.i4.364
32. Torres SM, Gomes FO, Nogueira GA. Characterization of individuals with venous ulcers in Brazil and Portugal. *Enferm Glob*. 2013;12 (32):200–213.
33. I Bou JE T, Rueda López J, Soldevilla Agreda JJ, Martínez Cuervo F, Verdú J. First national prevalence study of pressure ulcers in Spain: epidemiology and defining variables of lesions and patients. *Gerokomos*. 2003;14(1):37–47.
34. Rostra Ovejero V. Variability in clinical practice in the care of pressure ulcers [Internet]. 2016 Available from: https://es.slideshare.net/slideshow/variabilidad-en-la-practica-clnica-en-el-cuidado-de-las-lceras-por-presin/62490922. Accessed April 7, 2025.
35. International Working Group on the Diabetic Foot. IWGDF guidelines on the prevention and management of diabetic foot disease [Internet]. 2023 Available from: https://iwgdfguidelines.org/wp-content/uploads/2024/09/Guia-Espanol-IWGDF-2023.pdf. Accessed April 7, 2025.
36. Velnar T, Bailey T, Smrkolj V. The wound healing process: an overview of the cellular and molecular mechanisms. *J Int Med Res*. 2009;37 (5):1528–1542. doi:10.1177/147323000903700531
37. Rodrigues M, Kosaric N, Bonham CA, Gurtner GC. Wound healing: a cellular perspective. *Physiol Rev*. 2019;99(1):665–706. doi:10.1152/physrev.00067.2017
38. Ribatti D. The failed attribution of the Nobel prize for medicine or physiology to Viktor Hamburger for the discovery of nerve growth factor. *Brain Res Bull*. 2016;124:306–309. doi:10.1016/j.brainresbull.2016.02.019
39. Wee P, Wang Z, Leong KW. Epidermal growth factor receptor cell proliferation signaling pathways. *Cancers*. 2017;9(5):52. doi:10.3390/cancers9050052
40. Franklin JD, Lynch JB. Effects of topical applications of epidermal growth factor on wound healing: experimental study on rabbit ears. *Plast Reconstr Surg*. 1979;64(6):766–770. doi:10.1097/00006534-197912000-00003
41. Valdés J, Mantilla E, Marquez G, et al. Improving the expression of human epidermal growth factor in Saccharomyces cerevisiae by manipulating culture conditions. *Appl Biotechnol*. 2009;26(1):34–38.
42. Kriegel RJ, Soni S, Upadhyay A. Epidermal growth factor therapy and wound healing: past, present and future perspectives. *Surgeon*. 2018;16 (3):161–167.
43. Vidal EIO, Fukushima FB. The art and science of writing a scientific review article. *Cad Saude Publica*. 2021;37(4):e00063121. doi:10.1590/0102-311x00063121
44. Ilkeli E, Berna F, Demircan G, et al. Intralesional epidermal growth factor for diabetic foot ulcers. *J Coll Physicians Surg Pak*. 2022;32(3):278–282.
45. Çetinkaya Ö, Utku S, Erzincan B, Hazır B, Uncu H. Intralesional epidermal growth factor application is a potential therapeutic strategy to improve diabetic foot ulcer healing and prevent amputation. *Turk J Surg*. 2020;36(1):15–22. doi:10.5578/turkjsurg.4541
46. Kahraman M, Misir A, Bilge T, Ozcamdalli M, Uzun E, Mutlu M. The long-term outcomes following the application of intralesional epidermal growth factor in patients with diabetic foot ulcers. *J Foot Ankle Surg*. 2019;58(2):282–287. doi:10.1053/j.jfas.2018.08.041
47. Montequin F, Betancourt B, Leyva-Gonzalez G, et al. Intralesional administration of epidermal growth factor-based formulation (Heberprot-P) in chronic diabetic foot ulcer: treatment up to complete wound closure. *Int Wound J*. 2009;6(1):67–72. doi:10.1111/j.1742-481X.2008.00561.x
48. Fernández-Montequín JI, Infante-Cristiá E, Valenzuela-Silva CM, et al. Intralesional injections of Citoprot-P (recombinant human epidermal growth factor) in advanced diabetic foot ulcers with risk of amputation. *Int Wound J*. 2007;4(4):333–343. doi:10.1111/j.1742-481X.2007.00344.x
49. Berlanga-Acosta J, Savigne W, Valdez C, et al. Epidermal growth factor intralesional infiltrations can prevent amputation in patients with advanced diabetic foot wounds. *Int Wound J*. 2006;3(3):232–239. doi:10.1111/j.1742-481X.2006.00237.x
50. Tiaka EK, Papanas N, Manolakis AC, Georgiadis GS. Epidermal growth factor in the treatment of diabetic foot ulcers: an update. *Perspect Vasc Surg Endovasc Ther*. 2015;24(1):37–44. doi:10.1177/1531003512442093
51. Rahim F, Yan X, Shah JA, et al. Epidermal growth factor outperforms placebo in the treatment of diabetic foot ulcer: a meta-analysis [version 2; peer review: 2 approved]. *F1000Res*. 2023;11:773. doi:10.12688/f1000research.121712.2
52. Zhao DY, Su YN, Li YH, Yu TQ, Li J, Tu CQ. Efficacy and safety of recombinant human epidermal growth factor for diabetic foot ulcers: a systematic review and meta-analysis of randomised controlled trials. *Int Wound J*. 2020;17(4):1062–1073. doi:10.1111/iwj.13377
53. Bui TQ, Bui QV, Németh D, et al. Epidermal growth factor is effective in the treatment of diabetic foot ulcers: meta-analysis and systematic review. *Int J Environ Res Public Health*. 2019;16(14):2584. doi:10.3390/ijerph16142584
54. Cacua M, Buenahora G, Carrillo C. Effectiveness of the use of the human recombinant epidermal growth factor in the subsidized regime vs the contributive regime in patients with venous ulcers in Bogotá. *Drug Des Devel Ther*. 1933–1945;2024(18). doi:10.2147/DDDT.S437105
55. Cacua Sanchez MT, Vargas Abello LM, Á O, et al. Use of intralesional and perilesional human recombinant epidermal growth factor (hrEGF) in the local treatment of venous ulcers - review article - expert recommendation. *Vasc Health Risk Manag*. 2023;19:595–603. PMID:37701155;PMCID: PMC10494861. doi:10.2147/VHRM.S417447
56. Cacua Sanchez MT, Buenahora G. Socio-demographic characteristics and associated factors of morbidity in patients with venous ulcers treated in two institutions of contributive and subsidized regime in Colombia: retrospective, multicenter, observational study. *Vasc Health Risk Manag*. 2022;18:89–104. doi:10.2147/VHRM.S345542
57. Lee Y, Lee MH, Phillips SA, Stacey MC. Growth factors for treating chronic venous leg ulcers: a systematic review and meta-analysis. *Wound Repair Regen*. 2022;30(1):117–125. doi:10.1111/wrr.12982.

58. Cacua M, Sánchez L, Mejía J. Efficacy of recombinant human epidermal growth factor plus compression therapy versus hydrocolloid dressing plus compression therapy in the treatment of venous leg ulcers. *Wounds*. 2021;33(9):246–252. doi:10.32768/wound.2021.9.246-252
59. Cacua MT. Use of human recombinant epidermal growth factor in chronic wounds: experience in Colombia - review article. *Int J Innov Stud Med Sci*. 2020;4(4) ISSN 2457-063X (Online).
60. Mao C, Chen J, Li L. Clinical practice guideline for the use of growth factors in wound healing: a systematic review and meta-analysis of randomized controlled trials. *Ann Surg*. 2020;272(4):585–596. doi:10.1097/SLA.0000000000003959
61. Daza Arias J, García Dávila R, Lozano Herrera E, Tostano A. Una nueva alternativa en el manejo de la úlcera vascular compleja con factor de crecimiento epidérmico recombinante, Epiprot® (NEPIDERMINA). *Vascularium: Rev Latinoam Cir Vascular Angiol*. 2019;2(1):17–21.
62. Cacua MT, Giraldo LF. Experience with the use of perilesional and intralesional recombinant human epidermal growth factor (nepidermin) in the treatment of patients with chronic venous ulcers. *Vasc Dis Manag*. 2019;16(1).
63. Esquirol-Caussa J, Herrero-Vila E. Human recombinant epidermal growth factor in skin lesions: 77 cases in EPItelizando project. *J DermatolTreat*. 2019;30(1):96–101. doi:10.1080/09546634.2018.1468546
64. Ge MW, Hu FH, Jia YJ, et al. Efficacy of recombinant human epidermal growth factor in pressure injury healing: evidence from Chinese randomized controlled trials. *Wound Manag Prev*. 2024;70(1):1–11. PMID:38608161. doi:10.25270/wmp.22092
65. Fernández Montequín JI, Sancho Soutelo N, Fleitas Pérez E, et al. Heberprot-P como indicación terapéutica en el tratamiento curativo de las úlceras por presión. *Rev Esp Investig Quirúrg*. 2011;14(3):143–145.
66. García Ojalvo A, Berlanga Acosta J, Mendoza Marí Y, et al. 2022; Efectos sistémicos del tratamiento intralesional con factor de crecimiento epidérmico (Heberprot-P) en pacientes con úlceras de pie diabético. *Anales de la Academia de Ciencias de Cuba*. 12(1). Disponible en. Available from: https://revistaccuba.sld.cu/index.php/revacc/article/view/1088. Accessed June 10, 2025.
67. García-Ojalvo A, Berlanga Acosta J, Figueroa Martínez A, et al. Systemic translation of locally infiltrated epidermal growth factor in diabetic lower extremity wounds. *Int Wound J*. 2019;16(6):1294–1303. doi:10.1111/iwj.13189
68. García Ojalvo A, Berlanga Acosta J, Mendoza Marí Y, et al. Healing enhancement of diabetic wounds by locally infiltrated epidermal growth factor is associated with systemic oxidative stress reduction. *Int J Low Extrem Wounds*. 2022;21(1):49–59. doi:10.1177/15347346211060467
69. Espitaleta O, Román C, Gaviria NÁ, et al. EGF in the treatment of electrical burns and the decrease of bone resorption. Wounds International. Disponible en Available from: https://woundsinternational.com/journal-articles/egf-in-the-treatment-of-electrical-burns-and-the-decrease-of-bone-resorption/. Accessed March 7, 2024.
70. Espitaleta O, Montoya M, Barranco L, et al. Electrical burn: case report, multidisciplinary treatment and effectiveness of treatment with recombinant epidermal growth factor. *RevMédClín Las Condes*. 2024;35(1):45–52. doi:10.1016/j.rmclc.2023.12.004
71. Coerper S, Beckert S, Küper MA, Jekov M, Königsrainer A. Fifty percent area reduction after 4 weeks of treatment is a reliable indicator for healing: analysis of a single-center cohort of 704 diabetic patients. *J Diabetes Complications*. 2009;23(1):49–53. doi:10.1016/j.jdiacomp.2008.02.001.
72. Margolis DJ, Berlin JA, Strom BL. Risk factors associated with the failure of a venous leg ulcer to heal. *Arch Dermatol*. 1999;135(8):920–926. doi:10.1001/archderm.135.8.920
73. Schultz G, Bjarnsholt T, James GA, et al. Consensus guidelines for the identification and treatment of biofilms in chronic nonhealing wounds. *Wound Repair Regen*. 2017;25(5):744–757. doi:10.1111/wrr.12589
74. Mesmer MT, Cushing KA, Zgonis T. Immunohistochemistry and molecular biology of skin in patients with chronic venous insufficiency and venous ulcers: a review. *Clin Podiatr Med Surg*. 2018;35(2):259–271. doi:10.1016/j.cpm.2017.11.008
75. Choi JS, Leong KW, Yoo HS. In vivo wound healing of diabetic ulcers using electrospun nanofibers immobilized with human epidermal growth factor (EGF). *Biomaterials*. 2008;29(5):587–596. doi:10.1016/j.biomaterials.2007.10.012
76. Mohan VK. Recombinant human epidermal growth factor (REGEN-D 150): effect on healing of diabetic foot ulcers. *Diabet Res Clin Pract*. 2007;78(3):405–411. doi:10.1016/j.diabres.2007.06.004
77. Júbiz Pacheco Y, Grillo Ardila CF, Pardo Turriago R, et al. Guía de práctica clínica para el diagnóstico y tratamiento de los pacientes con pie diabético complicado. Bogotá: Asociación Colombiana de Diabetes; 2019. Available from: https://asodiabetes.org/wp-content/uploads/2021/04/GuiaPractica-1.pdf. Accessed June 10, 2025.
78. López-Ramos AK, Arrieta-Paredes MP, Reyes-Morales H. Economic evaluation of the use of recombinant human epidermal growth factor in diabetic foot ulcers in Mexico. *Value Health Reg Issues*. 2014;3:11–17. doi:10.1016/j.vhri.2014.03.002
79. Rodríguez J, Moncada L, Jaimes F. Cost-effectiveness of recombinant human epidermal growth factor in diabetic foot ulcer treatment in Colombia. *Value Health Reg Issues*. 2018;16:40–44. doi:10.1016/j.vhri.2018.03.002
80. Osorio J, Gómez S, Villegas L. Cost-effectiveness analysis of recombinant human epidermal growth factor versus negative pressure therapy for the treatment of diabetic foot ulcers in Colombia. *J Wound Care*. 2021;30(Suppl 5):S30–S36. doi:10.12968/jowc.2021.30.Sup5a.S30
81. Cacua M, Botero A, Moreno O. Cost-effectiveness analysis of intralesional and perilesional recombinant human epidermal growth factor vs hydrocolloid therapy in venous ulcer treatment in the Colombian context. *J Vasc Surg Venous Lymphat Disord*. 2024;12(2).

Drug Design, Development and Therapy

Dovepress
Taylor & Francis Group

Publish your work in this journal

Drug Design, Development and Therapy is an international, peer-reviewed open-access journal that spans the spectrum of drug design and development through to clinical applications. Clinical outcomes, patient safety, and programs for the development and effective, safe, and sustained use of medicines are a feature of the journal, which has also been accepted for indexing on PubMed Central. The manuscript management system is completely online and includes a very quick and fair peer-review system, which is all easy to use. Visit http://www.dovepress.com/testimonials.php to read real quotes from published authors.

Submit your manuscript here: https://www.dovepress.com/drug-design-development-and-therapy-journal